

Clear Cell Sarcoma: A Rare Aggressive Tumor with Potential Diagnostic Challenge

Adam Goldman¹, Matthew Doscher¹, Neil Lancaster², Paul Lamberti¹

Abstract

Introduction: Synovial sarcomas of the hand are extremely rare, high grade, slow growing, malignant soft-tissue neoplasms. They represent only a fraction of soft-tissue sarcomas, are usually found in the lower extremities around tendon sheaths, bursae, and joint capsules, and carry a significant risk for recurrence and eventual metastasis to the lymph nodes and lungs. There are limited reports of synovial sarcomas of the hand.

Case Report: A 67-year-old male presented with a slow-growing soft-tissue mass of the proximal right long finger over the course of one year. Initial excision was performed, which provided a diagnosis of monophasic synovial cell sarcoma. Subsequently, the patient underwent further staging with an eventual ray resection of the right long finger and an index ray transfer.

Conclusion: There are unique approaches to a patient with a highly malignant neoplasm in the hand. By performing a ray resection and index ray transfer, the patient was spared the potential side effects of radiation therapy and provided a quality functional and cosmetic outcome. The patient returned to work 4 weeks postoperatively. To the best of our knowledge, this treatment has not been used for a synovial sarcoma of the hand.

Keywords: Hand, synovial sarcoma, soft-tissue sarcoma, soft-tissue neoplasms

Introduction

Synovial sarcomas are malignant soft-tissue sarcomas that most frequently arise in close proximity to large joints of the extremities [1]. They most commonly present as a slow growing, deep, and palpable mass that are associated with pain or tenderness [1]. Given their insidious onset, many are initially diagnosed as myositis, hematoma, synovitis, tendonitis, or bursitis, delaying proper diagnosis and resulting in many being treated by unplanned excision [2]. Synovial sarcomas carry a significant risk for recurrence and eventual metastasis to the lymph nodes and lungs, making proper early diagnosis, appropriate intervention, and close follow-up important [1, 3]. The mainstay of treatment is wide excision with an adequate margin and maximal preservation of function; however, there is debate about the use of radiation and chemotherapy [1, 4, 5]. The presentation of a

synovial sarcoma in the hand is extremely rare, and as such, there have been limited case reports in the past 15 years [1, 6, 7]. Given the highly malignant nature of synovial sarcomas, it is essential that clinicians maintain a high index of suspicion for this rare tumor and be aware of the appropriate management of such cases.

Case Report

A 67-year-old right-hand dominant male with a past medical history of Hodgkin lymphoma s/p chemotherapy in remission, prostate cancer currently undergoing radiation treatment, and nephrolithiasis requiring multiple surgical interventions in the past, presented to the hand clinic with a chief complaint of a slowly growing right long finger mass over the last year. At the time of presentation, the patient denied any significant pain, weakness, or paresthesias. He had a CT scan before the presentation to

the hand clinic showing a focal, homogenous, and lobulated soft-tissue mass adjacent to the distal aspect of the long finger proximal phalanx (Figs. 1 and 2). He underwent a local excision with a mini Brunner incision over the proximal phalanx. The gross appearance was a 2.7 x 1.4 x 1.2 cm pink-tan partially encapsulated friable to rubbery fleshy portion of tissue. The diagnosis of monophasic synovial cell sarcoma was confirmed. Before further surgery, the patient had a CT scan of the chest/abdomen/pelvis for, further staging that showed stable, unchanged pulmonary nodules from prior CT scans 3 years before. The patient underwent a ray resection of the right long finger with an index ray transfer to the long finger space. The ray transfer was held with a double plate construct. Surgical pathology showed a minute particle (0.2 mm) of spindle cell tumor with margins clear of malignancy and no bony invasion. It was considered a

¹Department of Orthopaedics, John H. Stroger, Jr. Hospital of Cook County, Chicago, Illinois, USA,

²Department of Orthopaedics, Franciscan Health- Olympia Fields, Illinois, USA.

Address of Correspondence

Dr. Adam Goldman,
Orthopedic Surgery Resident, Franciscan Health Olympia Fields
20201 S. Crawford Ave, Olympia Fields, IL 60461.
E-mail: adamgoldman91@gmail.com



Dr. Adam Goldman



Dr. Matthew Doscher



Dr. Neil Lancaster



Dr. Paul Lamberti

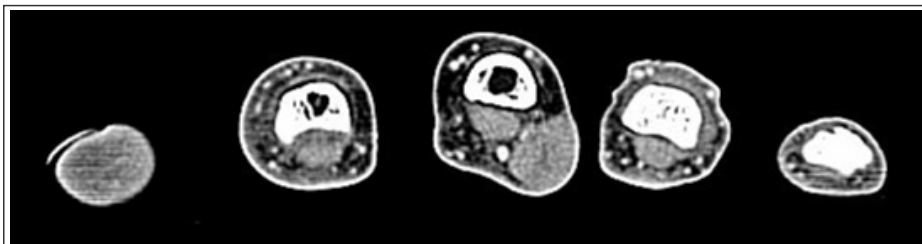


Figure 1: Axial cut of computed tomography scan demonstrating mass in the long finger.

Grade 3 on the French Federation of Cancer Centers Sarcoma Group. Fig. 3 demonstrates the first follow-up X-rays. Fig. 4 shows the healed osteotomy site and the final follow-up 4 months s/p ray transfer. Fig. 5 shows the patient's hand and healed incisions. The plan is for annual follow-up to monitor for any local recurrence or metastatic disease.

Discussion

Synovial sarcomas are high-grade malignant soft-tissue neoplasms that represent 5–10% of all soft-tissue sarcomas [1]. They present most commonly between ages 15 and 40 as a slow growing, painful mass with a male-to-female ratio of 1.2:1 [1]. The tumors tend to grow around tendon sheaths, bursae, and joint capsules with only <5% involved intra-articularly. Due to their location, many initial diagnoses include myositis, hematoma, synovitis, tendonitis, and bursitis which delay the proper diagnosis and treatment [1]. Early diagnosis is important due to the risk of eventual metastases to the lymph nodes (20%) and lungs (80%) [8]. The lower extremity is the most common site (60%) with most found around the knee and ankle [7]. The upper extremity accounts for 10–20% of the synovial sarcoma cases with only 4–8.5% occurring in the hand, usually

on the dorsal aspect [1, 6, 7]. There is less soft-tissue coverage in the hand compared to the knee and thigh, so patients usually present earlier in the disease process [3].

Risk factors with a worse prognosis include size >5 cm, deep seated, inadequate surgical resection, local recurrence, patient age >20, monophasic subtype, and mitotic activity >30 per high powered field [1, 9]. Due to size being one of the risk factors most important to recurrence and metastases, it is crucial to keep a high index of suspicion when diagnosing tumors of the hand. Unfortunately, there is no guidance on the acceptable margin for a synovial sarcoma tumor of the hand; however, most authors use a value of 2 cm [1].

There is debate about the recommended treatment for synovial sarcoma of the hand with no standard of care. While authors agree on excision, the use of radiation differs. It is shown to decrease local recurrence but does not affect overall survival [4, 10]. There was a significant decrease in local recurrence risk with radiation in those with marginal resection, but no difference in patients with a wide resections [1, 5]. There is no evidence that chemotherapy improves progression-free survival or overall survival, but may be used for those with metastases [1, 4, 10].

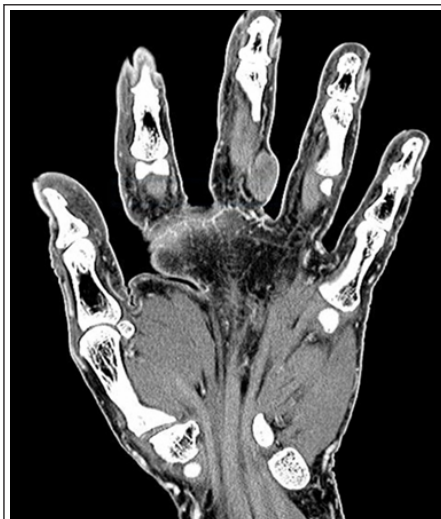

Figure 2: Coronal cut of computed tomography scan demonstrating mass in the long finger.

There have been limited case reports in the past 15 years on synovial sarcomas of the hand. Outani et al. performed a retrospective review on 137 patients diagnosed with synovial sarcoma at their institution, of which included five cases that involved the hand. Two underwent marginal excision with chemotherapy and radiation, one had a wide excision without chemotherapy or radiation, one had a double ray amputation with chemotherapy and radiation, and one refused surgery. Those who had surgery were disease-free on follow-up. The patient that refused surgery had distant metastases and died [6]. Michal et al. performed a retrospective review on 13 patients with “minute” synovial sarcoma of the hand measuring <1 cm in greatest diameter. They found that patients with complete follow-up did not develop metastases, but four patients out of the full 21 (included feet and hands) had local

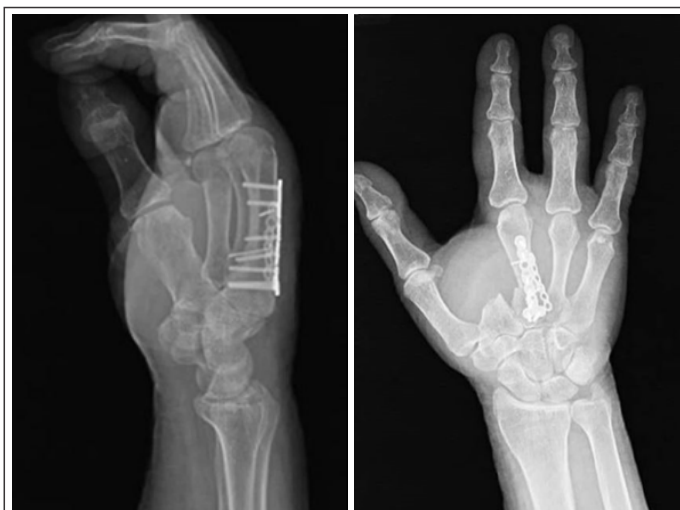

Figure 3: Initial 2-week follow-up X-rays.

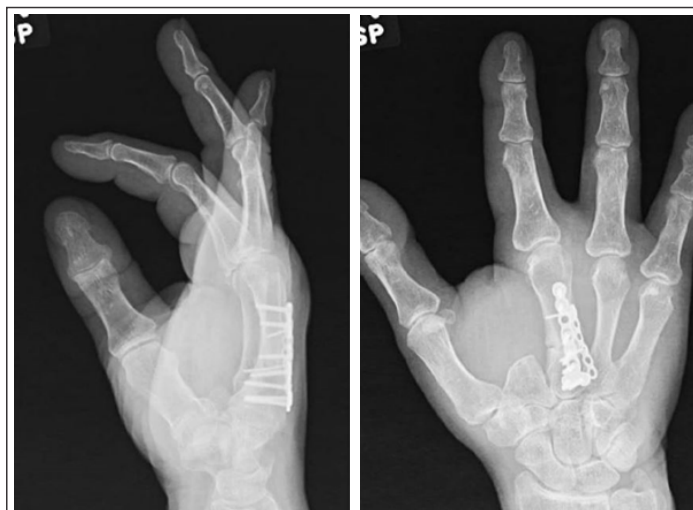

Figure 4: Four-month follow-up X-rays.

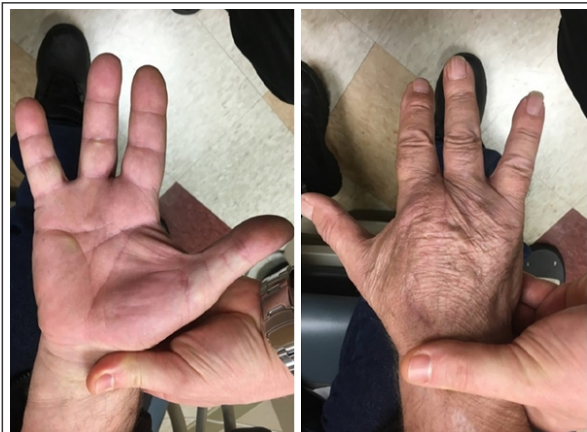

Figure 5: Healed incisions at 4 months.

recurrences. This shows the importance of regular follow-up and that the small synovial sarcomas have a low likelihood of metastases [3].

Our patient presented as a unique case due to the location on the proximal finger. While most authors recommend wide excision for synovial sarcoma of the hand, due to the

location at the proximal extent of the finger, it was thought that a ray resection would be the ideal treatment to maintain a relative normal anatomy of the hand. A ray amputation with ray transfer was performed to obtain clean margins, give the patient the maximum utility of his hand, and prevent a “gap hand” between the index and ring fingers. With this technique, there was adequate soft-tissue coverage, so a free flap was not required for closure. As been described, a ray resection in tumor cases has a very low rate of recurrence [11]. Since clean margins were obtained, it was decided that radiation was not necessary. In addition, radiation can cause contractures and stiffness of the hand which severely limit function. Chemotherapy was not used because there was no evidence

of metastases. The patient returned to work as a truck driver 4 weeks postoperatively. The plan is to follow-up annually to determine if there is any local recurrence with the possibility of CT scans of the lungs to rule out any metastases. We will follow this patient long term to determine if this is an adequate treatment protocol for localized synovial sarcoma of the hand.

Conclusion

We present a unique treatment for synovial sarcoma of the finger with good functional short-term results and outcome. A ray amputation with ray transfer may be considered for those patients with the rare diagnosis of synovial sarcoma of the hand and can be expanded to other aggressive neoplasms of the hand and fingers.

References

1. Siegel HJ, Sessions W, Casillas MA Jr., Said-Al-Naief N, Lander PH, Lopez-Ben R. Synovial sarcoma: Clinicopathologic features, treatment, and prognosis. *Orthopedics* 2007;30:1020-7.
2. Rosa AC, Machado MM, Filho LEG, Albertotti F, Sato E, Figueiredo MAJ et al. Sarcoma sinovial fibroso do pe: Relato de caso. *Radiol Bras* 2002;35:51-4.
3. Michal M, Fanburg-Smith JC, Lasota J, Fetsch JF, Lichy J, Miettinen M. Minute synovial sarcomas of the hands and feet: A clinicopathologic study of 21 tumors less than 1 cm. *Am J Surg Pathol* 2006;30:721-6.
4. Okcu MF, Munsell M, Treuner J, Mattke A, Pappo A, Cain A, et al. Synovial sarcoma of childhood and adolescence: A multicenter, multivariate analysis of outcome. *J Clin Oncol* 2003;21:1602-11.
5. Pradhan A, Cheung YC, Grimer RJ, Peake D, Al-Muderis OA, Thomas JM, et al. Soft-tissue sarcomas of the hand: Oncological outcome and prognostic factors. *J Bone Joint Surg Br* 2008;90:209-14.
6. Outani H, Hamada K, Oshima K, Joyama S, Naka N, Araki N, et al. *Clinical outcomes for patients with synovial sarcoma of the hand. Springerplus* 2014;3:649.
7. Sahoo TK, Dhal I, Das SK, Majumdar SK, Parida DK. Synovial sarcoma of palmar aspect of hand and survival: A rare case report. *J Clin Diagn Res* 2017;11:XD9-11.
8. Eilber FC, Dry SM. Diagnosis and management of synovial sarcoma. *J Surg Oncol* 2008;97:314-20.
9. Italiano A, Penel N, Robin YM, Bui B, Le Cesne A, Piperno-Neumann S, et al. Neo/adjuvant chemotherapy does not improve outcome in resected primary synovial sarcoma: A study of the French sarcoma group. *Ann Oncol* 2009;20:425-30.
10. Maia DC, Menezes CK, Bastos TC, de Lima Ferreira LC, Francesconi F. Poorly differentiated synovial sarcoma in the wrist: Case report. *An Bras Dermatol* 2014;89:816-18.
11. Puhaindrain ME, Healy JH, Athanasian EA. Single ray amputations for tumors of the hand. *Clin Orthop Relat Res* 2010;468:1390-5.

Conflict of Interest: NIL
Source of Support: NIL

How to Cite this Article

Goldman A, Doscher M, Lancaster N, Lamberti P | Clear Cell Sarcoma: A Rare Aggressive Tumor with Potential Diagnostic Challenge | *Journal of Bone and Soft Tissue Tumors* | May-August 2020; 6(2): 9-11.