

Health-Related Quality of Life in Patients with Bone Tumor around the Knee after Resection Arthrodesis

Wilasinee Sirichativapee¹, Weerachai Kosuwon¹, Winai Sirichativapee¹

Abstract

Background: This study aimed to compare the health-related quality of life (HRQoL) of patient with bone tumor around the knee after resection arthrodesis.

Methods: Patients between 15 and 70 years of age who underwent resection arthrodesis in Srinagarind Hospital more than >1 year were recruited. Patients were interviewed using a short form-36 questionnaire (social functioning-36 [SF-36] Ver2.0 Thai version) regarding their daily life problems.

Results: Eighteen-patients with the mean age of 36.6 years (15–63 years) were included. (15 females) in the study. Histological diagnoses were giant cell tumor GCT 10 cases, osteosarcoma 7 seven cases, and low-grade chondrosarcoma 1 one case. Site of lesions were was distal femur 15 cases and proximal tibia 3 cases. According to HRQoL health related quality of life, patients have good quality of life (score SF-36 >70) in all domains; (Mean score: Physical functioning 75.55±21.88, role-physical 71.18±22.70, bodily-pain 85.41±22.51, vitality 77.43±16.76, general health 74.44±19.16, social functioning SF83.05±26.40, role-emotional 80.09±22.89, and mental health 77.77±21.29). Complications post-operative are broken implants (3 cases, 16.7%) and infections (4 cases, 22.2%).

Conclusion: In patients with bone tumor around the knee after resection, arthrodesis have a good quality of life in all domains in SF-36 version 2.0 questionnaire including function, pain, and mentality.

Keywords: Limb salvage, Arthrodesis, Quality of life, social functioning SF-36 version 2.0, Osteosarcoma, Giant cell tumor.

Introduction:

The knee is a common site for bone tumors, primary malignant and aggressive benign bone tumors, whether clinically painful or not. The most common aggressive benign bone tumor is giant cell tumor (GCT) (the second most common of benign bone tumor) [23] and the most common primary malignant bone tumor is osteosarcoma [4]. Treatments of malignant and aggressive bone tumor in adult have significant advancement. As a result of advances management including neoadjuvant chemotherapy, surgical technique, radiation, and survival rates improved considerably. Surgery offers local control of tumor while chemotherapy provides a general control of disease (micrometastasis) [1, 2]. The interesting in limb salvage has increased significantly because it is an attractive

procedure to amputation [3]. The increasing number of limb salvage procedure is significant the importance to assess health-related quality of life (HRQoL) in this patient. Wide resection of tumor results in loss of bone, muscle, even, entire the joints. Reconstruction of bone defect following wide resection of malignant or aggressive benign bone tumors around the knee is a critical problem in orthopedic surgery. Several options are available for reconstruction such as endoprosthesis, allograft-prosthesis composite (APC), and even arthrodesis [24]. It is difficult to choose the best treatment for each particular patient due to several factors such as site, pathology, life expectancy, predicted function of limb, patient's demand, expectation, and economy [27]. An ideal bone and joint reconstructions should be

durability in weight-bearing lower extremities. Several previous studies are comparing HRQoL between limb salvage and amputation [5, 6, 7, 9], but no study is focusing in HRQoL of patients who underwent arthrodesis. The purpose of this study was to access the HRQoL in patients following knee resection arthrodesis. We also examine the complications and daily life problem in this patient population.

Patients and Methods

Patients

A retrospective review was made of 18 patients with various primary malignant and aggressive benign bone tumors around the knee who underwent limb salvage surgery and reconstruction with arthrodesis in Srinagarind Hospital. There are 300–350 patients with bone and soft tissue tumor every year in Srinagarind Hospital. Between 2004 and 2014, there were 30 patients who undergo knee resection arthrodesis. Patients were eligible if they were aged between 15 and 70 years. The time since surgery was >12 months. The malignant and aggressive benign bone tumors were

¹Department of Orthopaedics, Faculty of Medicine, KhonKaen University, KhonKaen, Thailand.

Address of Correspondence

Dr. Winai Sirichativapee,
Department of Orthopaedics, Srinagarind Hospital, 123
KhonKaen University, NaiMueang Sub-District, Mueang
District, KhonKaen Province - 40002, Thailand.
E-mail: winaisiri@yahoo.com



Dr. Wilasinee
Sirichativapee



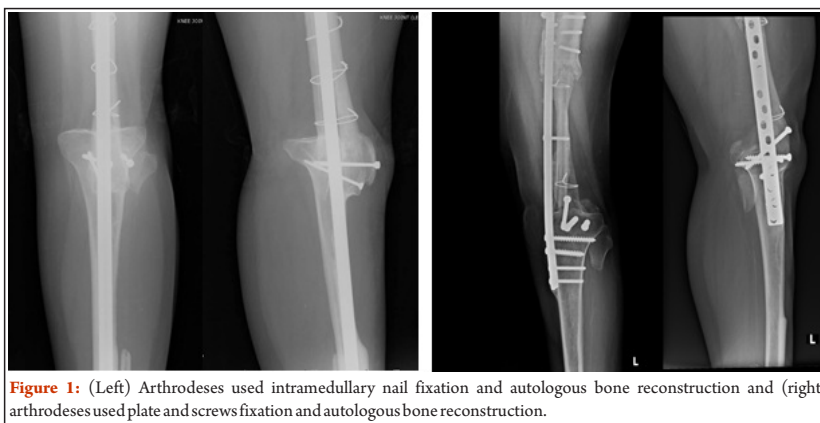
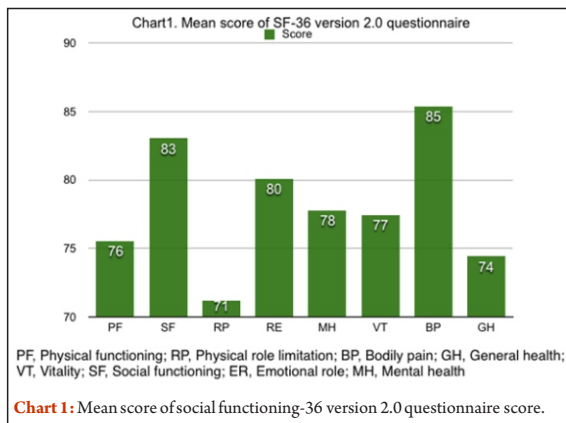
Dr. Weerachai
Kosuwon



Dr. Winai
Sirichativapee

© 2017 by Journal of Bone and Soft Tissue Tumors | Available on www.jbstjournal.com | doi:10.13107/jbst.2454-5473.146

This is an Open Access article distributed under the terms of the Creative Commons Attribution Non-Commercial License (<http://creativecommons.org/licenses/by-nc/3.0/>) which permits unrestricted non-commercial use, distribution, and reproduction in any medium, provided the original work is properly cited.



located at distal femur or proximal tibia and the surgical intervention consisted of arthrodesis. All patients must understand the Thai language and the questionnaire and also medical records of patients must have pathological reports, surgical technique, and follow-up data. Patients were not included if they cannot be contacted. This study was carried out according to the Declaration of Helsinki and the KhonKaen University Ethics Committee for Human Research approved the study protocol(HE591218).

Surgical technique

After wide resection of the tumor, arthrodesis of knee was performed in various ways. Arthrodeses were fixed by intramedullary nail or plate fixation. Bone reconstruction consisted of autologous bone graft (femoral turn-down or tibial turn up combined with fibular strut graft) or allograft (Fig.1).

Patient assessment

All patients had clinical assessment consisted partly of questionnaire and partly of interview. All patients were interviewed using Thai short form-36 version 2.0 when they came follow-up at orthopedic clinic in Srinagarind Hospital. Thai social functioning-36(SF-36)version 2.0 has been validated[14], self-administered measure evaluating eight domains: Physical functioning (PF), physical role limitation, bodily pain, general health (GH), vitality, SF, emotional role, and. SF-36 consisted of 36 questions, each domain scale from 0 (worst health status) to 100(best health status). Score >70 indicates good quality of life when compare to normal population. Thai SF-36 version2.0 was found to be sufficient for research purposes, with Cronbach's alpha ranging from 0.72 to 0.94. The patient interview aimed to evaluate which consequences of the surgery interfered their quality of life and complication from surgery.

number of operations are 3 times(5.6%), 2 times (16.7%), and single operation (77.8%) (Table1).

Quality of life assessment

Table 2 shows scores from SF-36 version 2.0 in each patient. Most of the patients have good quality of life in SF domain (score>70, 83.33%). More than two-third of patients have scored>70 in PF domain. However, almost half of patients show limitation in physical role domain (38.88%). From Chart1, means score of the study population shows scores >70 in all domains of SF-36 version 2.0 indicate that the study populations have good quality of life after resection arthrodesis. All patients who entered the study completed all the questionnaires. The patients consistently reported high quality of life on all domains of SF-36 version2.0. Daily life problems were unable to work and unable to bend the knee.

Complications

The complications from surgery consisted of broken implant (16.7%) and infection (22.2%). According to infection, 60% are found in patients who underwent allograft reconstruction. All patients were cured from infection, average time was 23 months. Organism of infections was Klebsiella pneumonia and Staphylococcus coagulase positive.

Discussion

Limb salvage procedure has replaced amputation as the treatment of primary bone tumor around knee. Limb salvage provides advantage in function, appearance and is considered to be cost-effective when compared with amputation. Arthrodesis is a choice of reconstruction after wide

Table 1: Demographic data	
	Patient
Number	18
Age(SD)	36.61(16.31)
Sex: Female, n (%)	15(83.33)
Diagnosis, n (%)	
Giant cell tumor	10(55.6)
Osteosarcoma	7(38.9)
Low-grade chondrosarcoma	1(5.6)
Site of lesion, n (%)	
Distal femur	15(83.3)
Proximal tibia	3(16.7)
Fixation, n (%)	
Plate and screws	8(44.4)
Nail	9(50)
Plate and nail	1(5.6)
Number of operation, n (%)	
3	1(5.6)
2	3(16.7)
1	14(77.8)

Statistical analysis

All analyses were performed using SPSS version 19. Descriptive statistics included calculation of frequencies and percentage for demographic data and surgical technique. Mean and standard deviation used for clinical variable.

Results

Patients characteristics

The study populations consisted of 18 patients 15–67 years go age with mean age of 36.61 years (standard deviation 16.31): 83.33% of patients were women. The diagnosis is GCT (55.6%), osteosarcoma (38.9%), and low-grade chondrosarcoma (5.6%). Site of lesionis distal femur (83.3%) and proximal tibia (16.7%). A

Table 2: Patient identification and scores

ID	Sex	Diagnosis	Site	Complication	PF	RP	BP	GH	VT	SF	RE	MH
1	F	GCT	DF	1	40	56.25	100	60	50	100	75	55
2	F	GCT	DF		90	87.5	100	80	87.5	100	91.66	95
3	F	GCT	DF		95	87.5	100	70	87.5	100	100	75
4	F	OS	DF	2,3	75	62.5	100	95	93.75	100	100	85
5	M	OS	DF	2	40	6.25	55	60	50	50	41.66	30
6	F	GCT	DF		80	75	65	70	75	87.5	83.33	80
7	F	OS	PT	3	85	56.25	62.5	35	56.25	50	41.66	55
8	F	OS	DF	1	20	31.25	22.5	35	37.5	25	33.33	30
9	F	LC	DF		65	93.75	80	90	87.5	100	83.33	85
10	F	OS	DF	2	80	75	65	55	81.25	87.5	50	75
11	M	OS	DF		90	87.5	100	90	87.5	100	100	90
12	F	GCT	DF	3	80	68.75	100	95	87.5	62.5	75	90
13	F	GCT	DF		85	87.5	100	80	81.25	100	91.66	95
14	F	GCT	DF	1,4	65	68.75	100	70	87.5	75	100	90
15	M	GCT	PT		90	81.25	100	85	87.5	100	91.66	90
16	F	GCT	PT		85	93.75	100	90	87.5	87.5	100	90
17	F	OS	DF	1	95	81.25	100	95	87.5	100	100	90
18	F	GCT	DF	3	100	81.25	87.5	85	81.25	100	83.33	100

GCT: Giant cell tumor, PF: Physical functioning, BP: Bodily pain, GH: General health, VT: Vitality, SF: Social functioning, MH: Mental health, RP: Physical role limitation

resection tumor that can provide more durable stability [22]. This study aimed to investigate HRQoL in patients who have primary malignant or aggressive benign bone tumor around the knee who underwent knee resection arthrodesis. According to HRQoL measures, patients reported significantly better score of SF-36 in all domains, physical and mental. Complications from surgery are infection and broken implant. According to infection, we found that patients who underwent allograft reconstruction have infected allograft (60%). However, all patients were cured and no one turns to amputation. Several studies have highlighted problem of infection after limb salvage, in which it is frequent as after using allograft [29, 30]. Apart from complications of surgery, patients reported their daily life function almost same as before surgery. According to our study, knee arthrodesis did not decrease the quality of life in the patients. In malignant or benign bone tumors, there are several treatment methods instead of arthrodesis and each technique has several advantages and disadvantages. The original arthrodesis using large segmental bone graft

to retain length was first reported by Putti and Juvara. It was later modified by Campanacci and Costa [28]. The advantages of arthrodesis are limb salvage surgery and patients also have leg for walking or working. On the other hand, the important disadvantage is limit motion of knee so it makes problem when patient using public transportation like bus. About preserving joint motion surgery, there are many choices such as endoprosthesis or APC. Endoprosthetic replacement from the previous study has many advantages such as early stability, early weight-bearing, motion of knee, functional outcome good to excellent, and cosmetic, but aseptic loosening, local recurrence, mechanical failure, fracture, and infection are disadvantages of this method that may limit the long-term survival of prosthesis and lead to risk of revision [24,25]. Reconstruction with the use of autologous graft and allograft also has several advantages and disadvantages to consider before chosen. Related to autologous bone graft, advantage is union rate and decreasing risk of transmitted disease, but limitation of this method is the limitation of bone stock after

wide resection [4]. However, for allograft, it can fill any size of bone defect because bone bank also has many size of bone, but patient has to deal with risk of delayed union, non-union, and also infection. Hence, there is not the best reconstruction method for every patient, but we have to consider the most suitable method for each patient. From previous study in quality of life after bone tumor surgery, which include limb salvage and ablative [11]. This study explored quality of life in patient who has bone tumor around the knee who aged 8–25 years. The study revealed significant worse score in quality of life in function domains. From SF-36, significantly lower scores in PF, role physical, GH and mental component. These results are similar with several studies earlier among patients with malignant of the leg that demonstrated lower HRQoL score in PF. However, from the previous several studies, they studied in general of limb salvage, prosthesis and arthrodesis, and amputation but no study which focuses just in the individual procedure. Our study is the first study to present the quality of life in patients who underwent resection arthrodesis that has higher scores when compared to healthy population. Our study, however, has limitation in the study design that was cross-sectional study so there are some differences in surgical procedure of arthrodesis, and in size of population was relatively small.

Conclusions

It is suggested that arthrodesis is a good treatment of choice for reconstruction after wide resection bone tumor around the knee. Score of SF-36 shows good quality of life in all domains including physical status and mental status.

References

- Durfee RA, Mohammed M, Luu HH. Review of osteosarcoma and current management. *Rheumatol Ther* 2016;3:221-43.
- Tiwari A. Current concepts in surgical treatment of osteosarcoma. *J Clin Orthop Trauma* 2012;3:4-9.
- Al-Zaben R, Alturk M, Alkhwaldah A, Al-Zaben A, Rahaymeh J. Limb salvage surgery for bone tumors around the knee: The oncological and functional outcome king Hussein medical center experience. *J U S China Med Sci* 2015 12:111-9.
- Asavamongkolkul A. *Bone and Soft-Tissue Tumors*. 1st ed. Bangkok, Lyon, France: IARC Press; 2013.
- Ramazzeni-Castro R, Pons-Cabrafiga M. Knee arthrodesis in rescue surgery: A study of 18 cases. *Rev Esp Cir Ortop Traumatol* 2013;57:45-52.
- Williamson A, Rattray K, Aird J, Gollgoly J, Heang O. Quality of life outcomes following knee arthrodesis in a resource poor setting. *Asian Biomed* 2013;7:113-7.
- Shchelkova OY, Usmanova EB. Quality of life and relation to disease in patients with bone sarcoma. *Psychol Russia* 2015;8:23-31.
- Demiralp B, Ege T, Kose O, Yurttas Y, Basbozkurt M. Reconstruction of intercalary bone defects following bone tumor resection with segmental bone transport using an ilizarov circular external fixator. *J*

OrthopSci 2014;19:1004-11.

9. Kim JD, Kwak JM, Chung SH. Quality of life in long-term survivors of osteosarcoma. *J Cancer Ther* 2013;4:

10. Lim LL, Seubsman SA, Sleigh A. Thai SF-36 health survey: Tests of data quality, scaling assumptions, reliability and validity in healthy men and women. *Health Qual Life Outcomes* 2008;6:52.

11. Bekkering WP, Vlieland TP, Koopman HM, Schaap GR, Schreuder HW, Beishuizen A, et al. Quality of life in young patients after bone tumor surgery around the knee joint and comparison with healthy controls. *Pediatr Blood Cancer* 2010;54:738-45.

12. Han G, Wang Y, Bi WZ. Study on the health-related quality of life in patients after surgery for malignant bone tumors. *Asian Pac J Cancer Prev* 2012;13:127-30.

13. Aksnes LH, Bauer HC, Jebsen NL, Follerås G, Allert C, Haugen GS, et al. Limb-sparing surgery preserves more function than amputation: A Scandinavian sarcoma group study of 118 patients. *J Bone Joint Surg Br* 2008;90:786-94.

14. Jirattananaphochai K, Jung S, Sumananont C, Saengnipanthkul S. Reliability of the medical outcomes study short-form survey version 2.0 (Thai version) for the evaluation of low back pain patients. *J Med Assoc Thai* 2005;88:1355-61.

15. Lian CW, Hua SM, Thon CC. Study on health-related quality of life in bone cancer patients. *Asian J Cancer* 2013;12:115-21.

16. Furtado S, Grimer RJ, Cool P, Murray SA, Briggs T, Fulton J, et al. Physical functioning, pain and quality of life after amputation for musculoskeletal tumours: A national survey. *Bone Joint J* 2015;97-B:1284-90.

17. Saikia KC, Bhuyan SK, Saikia SP, Rongphar R, Jitesh P. Resection and arthrodesis of the knee joint for giant cell tumours of bone. *J OrthopSurg (Hong Kong)* 2010;18:208-14.

18. Shih HN, Shih LY. Resection arthrodesis of the knee for osteosarcoma: An alternative when mobile joint reconstruction is not feasible. *Chang Gung Med J* 2005;28:411-20.

19. Capanna R, Scoccianti G, Campanacci DA, Beltrami G, De Biase P. Surgical technique: Extraarticular knee resection with prosthesis-

proximal tibia-extensor apparatus allograft for tumors invading the knee. *ClinOrthopRelat Res* 2011;469:2905-14.

20. Sharil A, Nawaz A, Azman MN, Zulmi W, Faisham W. Early functional outcome of resection and endoprosthesis replacement for primary tumor around the knee. *Malays Orthop J* 2013;7:30-5.

21. Renard AJ, Veth RP, Schreuder HW, van Loon CJ, Koops HS, van Horn JR, et al. Function and complications after ablative and limb-salvage therapy in lower extremity sarcoma of bone. *J SurgOncol* 2000;73:198-205.

22. Lv C, Tu C, Min L, Duan H. Allograft arthrodesis of the knee for giant cell tumors. *Orthopedics* 2012;35:e397-402.

23. Hakim DN, Pelly T, Kulendran M, Caris JA. Benign tumours of the bone: A review. *J Bone Oncol* 2015;4:37-41.

24. Merchán EC, Herrera SS, Lopez JM. Limb salvage procedures in osteosarcomas around the knee joint. *Sao Paulo Med J* 1994;112:661-7.

25. Myers GJ, Abudu AT, Carter SR, Tillman RM, Grimer RJ. Endoprosthetic replacement of the distal femur for bone tumours: Long-term results. *J Bone Joint Surg Br* 2007;89:521-6.

26. Tomić S, Lesić A, Bumbasirević M, Sopta J, Rakocević Z, Atkinson HD, et al. An aggressive chondroblastoma of the knee treated with resection arthrodesis and limb lengthening using the ilizarov technique. *J OrthopSurg Res* 2010;5:47.

27. Huang TL, Chen TH, Chen WY, Chen WM, Liu CL, Lo WH, et al. Allograft arthrodesis of the knee in high-grade osteosarcoma. *J Chin Med Assoc* 2005;68:425-30.

28. Campanacci M, Costa P. Total resection of distal femur or proximal tibia for bone tumours. Autogenous bone grafts and arthrodesis in twenty-six cases. *J Bone Joint Surg Br* 1979;61-B:455-63.

29. Renard AJ, Veth RP, Schreuder HW, van Loon CJ, Koops HS, van Horn JR, et al. Function and complications after ablative and limb-salvage therapy in lower extremity sarcoma of bone. *J SurgOncol* 2000;73:198-205.

30. Quinn RH, Mankin HJ, Springfield DS, Gebhardt MC. Management of infected bulk allografts with antibiotic-impregnated polymethylmethacrylate spacers. *Orthopedics* 2001;24:971-5.

Conflict of Interest: NIL
Source of Support: NIL

How to Cite this Article

Sirichativapee W, Kosuwon W, Sirichativapee W. Health-Related Quality of Life in Patients with Bone Tumor around the Knee after Resection Arthrodesis. *Journal of Bone and Soft Tissue Tumors* Jan-Apr 2019;5(1): 17-20.