An Interesting Reconstruction Option after Resection for a Distal Fibular Osteosarcoma: A Case Report

Manish Pruthi[1], Jagandeep Singh Virk[2], Lokesh Garg[1], Sumit Goyal[4], Anila Sharma[3]

Abstract

Fibula is an expandable bone in the body, but tumors arising from the distal part which require a wide resection of the distal fibular part require some form of reconstruction for preventing lateral ankle instability. Many methods involving either bony or soft tissue reconstruction techniques have been described in literature, but consensus regarding which one is optimal for a good oncological and functional outcome is lacking. In this case report, we make use of a biological soft tissue technique involving use of peroneus brevis autograft reconstruction for providing lateral ankle support for a patient suffering from distal fibular osteosarcoma who underwent resection of the distal fibula. The patient went on to have an excellent functional outcome. This technique, although reported in literature, is in the form of only a few cases with a limited follow-up with none reported from the Indian subcontinent.

Keywords: Fibula, Sarcomas, Limb salvage, Reconstruction.

Introduction

Primary fibular sarcomas are a rare entity with the distal fibular site even more rare as compared to the proximal site [1]. Osteosarcoma of the fibula is found in 2–5.6% of cases with the distal fibula constituting approximately 0.47% of patients [2].Unlike proximal and middle third part of the fibula which is expandable sites and does not require reconstruction after resection, the distal third part of the fibula requires definitive reconstruction for providing lateral ankle stability. Surgical resection with wide margins is paramount as part of optimal surgical management of sarcomas, but obtaining the same for distal fibular lesions may be hampered by difficulties with soft tissue coverage and the possible impact on foot and ankle biomechanics [3, 4]. Lateral ankle stabilization and soft tissue coverage after distal fibulectomy are recommended to prevent ankle instability and subsequent progression to ankle arthritis with accompanying disability [5].

In this case report, we aim to highlight a biological method of reconstruction after undertaking a distal fibular resection. In this method, we employ a peroneus brevis tendon autograft reconstruction method, ensuring adequate lateral ankle stability, and a good functional outcome. This technique is well-described in literature in a small case series of three patients but none have been reported from the Indian subcontinent [6].

Case Report

A 25-year-old female presented to us in January 2018 with complaints of pain and swelling over the lateral aspect of her left ankle joint for the past 1 month. She also complained of difficulty in walking and weight-bearing over the left ankle joint for a similar duration. After examining her clinically, a palpable swelling over the lateral aspect of the left ankle joint was appreciated. Radiographs of the involved part revealed a lytic lesion in the distal fibular region with periosteal reaction and permeation into the surrounding soft tissues (Fig. 1). Further, contrast-enhanced magnetic resonance imaging (MRI)was conducted for better delineation of the lesion (Fig. 2). Subsequently, a core needle biopsy of the lesion was conducted in view of the suspicious clinicoradiological findings of a malignancy. The Histopathology confirmed a telangiectatic variant of osteosarcoma of the lower end of fibula. Staging investigations in the form of non-contrastcomputed tomography scan of the chest and bone scan were done, which confirmed the lesion to be non-metastatic. The case was taken up for discussion in the weekly multidisciplinary tumor board and after consensus, a decision to start with neoadjuvant chemotherapy followed by definitive local therapy in the form of surgery and, lastly followed by adjuvant chemotherapy was made. The patient and relatives were counseled regarding the same and neoadjuvant chemotherapy as per our institutional protocol were started. The patient underwent three cycles of Ifosfamide, Cisplatin & Doxorubicin based chemotherapy at 3 weekly intervals.

[1]Department of Orthopaedic Oncology, Rajiv Gandhi Cancer Institute and Research Centre, New Delhi,Delhi, India,
[2]Department of Orthopaedic Oncology, Paras Hospitals, Panchkula,Haryana, India,
[3]Department of Pathology, Rajiv Gandhi Cancer Institute and Research Centre, New Delhi, Delhi, India,
[4]Department of Medical Oncology, Rajiv Gandhi Cancer Institute and Research Centre, New Delhi,India

Address of Correspondence
Dr. Jagandeep Singh Virk,
Department of Orthopaedic Oncology, Paras Hospitals, Panchkula,Haryana, India.
E-mail: jaganvirk_09@yahoo.co.in


Dr. Manish Pruthi


Dr. Jagandeep Singh Virk


Dr. Lokesh Garg


Dr. Sumit Goyal


Dr. Anila Sharma

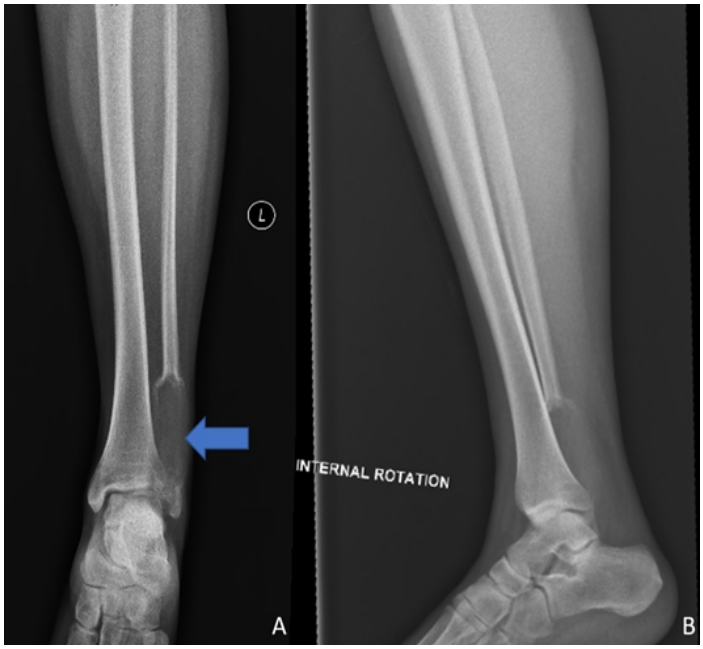

Figure 1: Radiographs anteroposterior (a) and lateral (b) view of the leg and ankle region showing a lytic lesion (blue arrow) in the distal fibular region with periosteal reaction, expansion of the cortices, and permeation into the surrounding soft tissues.

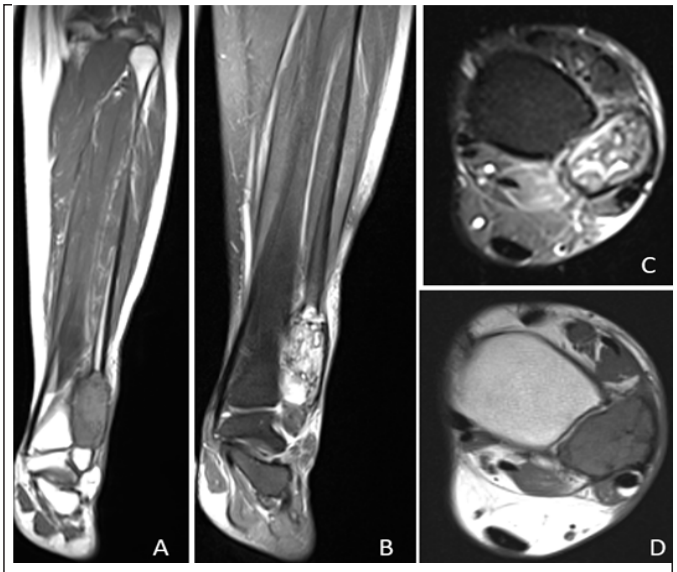

Figure 2: (a) T1-weighted coronal image showing a metadiaphyseal hypointense lesion in the lower fibular region causing cortical thinning and its erosions at multiple places. (b) Sagittal short tau inversion recovery (STIR) image showing a well-definedhyperintense metadiaphyseal lesion with surrounding soft tissue and muscle edema.(c)T2 axial mixed intensity hypointense lesion showing few internal cystic areas.(d) Axial STIR image showing hyperintense mass lesion with cortical breach and soft tissue extension anterolaterally with surrounding subcutaneous and muscular edema.

Following this patient was locally restaged with contrast-enhanced MRI of the involved part (Fig. 3). A decision to perform a limb salvage surgery in the form of resection with wide and safe margins and a biological reconstruction to provide lateral ankle stability was made.

The biological reconstruction technique as described by Monson et al. [6] was employed which involved the following major steps (Fig. 4):

1. During resection of the distal fibular sarcoma, talofibular and calcaneofibular ligament were tagged
2. Peroneus brevis tendon was identified and cut at its myotendinous junction
3. Distally peroneus brevis tendon stitched to talofibular ligament with Ethibond no. 2 suture
4. Double armed suture anchor was inserted in middle of tibia lateral surface 1.5 cm above distal articular surface of tibia
5. Threads of suture anchor were used to secure peroneus brevis tendon to tibia keeping foot in neutral position and proper tension in tendon before being reflected for rest of lateral ankle ligament reconstruction.
6. Then, anterior talofibular and calcaneo fibular ligaments were secured with Ethibond no. 2 sutures and sutured to the distal edge of the flipped peroneus brevis tendon
7. The peroneus brevis tendon was further tenodesed with the distal tibia with a Richards staple.

Figure 3: Post-neoadjuvant chemotherapy magnetic resonance imaging (MRI) images (a) T1 coronal, (b) T2 short tau inversion recovery (STIR) coronal, (c) T2 axial STIR, and (d) T1 axial images showing resolution of peritumoral edema as compared to pre-neoadjuvant chemotherapy MRI with better delineation of the lesion in the lower end of fibula.

A below-knee slab with the foot in neutral position was applied for 2 weeks. Following this, a below-knee cast is applied for another 4 weeks. The patient was kept non-weight bearing over the operated limb for 6 weeks following which a removable ankle brace (ankle foot orthosis) was given for 3 months and a lateral ankle support for another 3 months. Gradual weight-bearing and supervised ankle range of motion exercises were started.

The final histopathological examination confirmed the resection margins to be free and the patient was resumed on adjuvant chemotherapy 2 weeks following the surgery. Following the completion of adjuvant chemotherapy, the patient is presently under surveillance and has completed 24 months of disease-free period. The patient went on to have an excellent ankle function (musculoskeletal tumor society score- 28) with the patient able to perform almost all activities of daily living without any lateral ankle instability [7]. Her follow-up radiographs showed maintained ankle joint line with no evidence of instability/arthritis (Fig. 5).

Discussion

Given the rarity of distal fibular sarcomas, there is paucity of data in literature on how to best manage these tumors. There is no consensus on the best method of reconstruction, given the multitude of options available for reconstruction of the distal fibular defect and lateral ankle stability. Fibula, although an expandable site for bone tumors and no reconstruction, is usually required when the tumoris located in the proximal and middle third segments, the same cannot be said about distal fibular

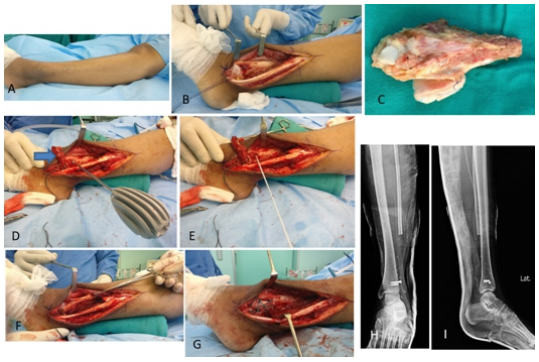

Figure 4: (a) Pre-operative image showing the surgical site marked over the involved leg, (b)lateral ankle ligaments (anterior talofibular and calcaneofibular) tagged with sutures and defect left behind after fibular resection, (c)resected specimen, (d)peroneus brevis tendon harvested (blue arrow) and sectioned proximally and secured with artery forceps and suture anchor inserted into the distal tibial region, (e)threads of suture anchor, (f)peroneus brevis tendon secured to the distal tibial region, (g)lateral ankle ligaments secured with Ethibond no. 2 sutures and sutured to the distal edge of the flipped peroneus brevis tendon and peroneus brevis tendon further tenodesed with the distal tibia with a Richards staple H and I. Anteroposterior and lateral post-operativeradiographs showing good position of the ankle mortise with the Richards staple and suture anchor insitu.

resections. Although there are few studies [8, 9] which have not performed a reconstruction after a distal fibular resection, there is sufficient proof in literature to highlight the complications which can arise from the destabilizing effect from a distal fibular resection on the lateral ankle stability. Complications such as progressive valgus deformity [10], gait abnormalities from ankle contractures and abnormal talar tilt [11], ankle and subtalar arthritis, and growth plate injury of the immature distal tibia have been reported due to failed/nonreconstruction of the distal fibular defect [5, 12].

Various methods for reconstruction of the lateral ankle stability after distal fibulectomy have been described in literature. Techniques such as reattachment of lateral ligaments to the distal tibia [13], mobilization of proximal fibula, allograft or recycled autograft reconstruction [14, 15], and arthrodesis of the tibiotalar joint [16] have been described. These techniques have their own merits, but they have been associated with complete loss of motion in the ankle and subtalar joints accompanied by the risk of failed or delayed arthrodesis in patients undergoing adjuvant therapy in the form of radiotherapy or chemotherapy for systemic cancer management. Other described complications include: Periprosthetic fractures, destabilization of the proximal tibiofibular joint when the proximal fibula is mobilized distally, and wound and hardware complications [14, 15, 16, 17].

Techniques involving use of tendons such as split tibialis posterior tendon transfer to remaining peroneus brevis or using peroneus brevis tendon itself for providing lateral ankle stability after bony resection have also been described in literature with good results [6, 18]. The technique which was used for our patient is a biological method which involved the peroneus brevis autograft and provided excellent lateral ankle stability and functional outcome. This technique is well described in literature by Monson et al. in a case series of three patients will a similar excellent outcome. It does not involve extending the incision for harvesting the proximal fibula as would be required if contemplating a bony reconstruction. It also circumvents the problems associated with tibiotalar arthrodesis, donor site morbidity, and nonunion when grafts are used. This technique provides sufficient mechanical strength, lateral ankle stability, and ideal tissue for lateral ankle ligament reconstruction. The patient has been able to resume all her activities of daily living without experiencing any discomfort, ankle arthritis, or instability in her ankle joint till her last follow-up. The only limitation of our case report is the requirement of a longer follow-up with many more patients with this reconstruction modality to confirm our results.

Figure 5: (a and b)Anteroposteriorand lateral radiograph on follow-up at 18 months post-surgery showing maintained ankle joint line with no evidence of arthritis with anchor screw and staplerinsitu.

Conclusion/Clinical Relevance

The technique of utilizing peroneus brevis tendon for reconstruction of lateral ankle stability after distal fibular resection for malignant bone lesions if feasible as gauged on the planning MRI is biological and simple, utilizes the same incision/operative area as already exposed at the time of resection, and gives excellent functional outcome.

References

1. UnniKK. Dahlin's Bone Tumors: General Aspects and Data on 11087 Case. 5th ed. Philadelphia, PA: Lippincott-Raven; 1996. p. 1-9.

2. PerisanoC, MarzettiE, SpinelliMS, GraciC, FabbricianiC, MaffulliN, et al.Clinical management and surgical treatment of distal fibular tumours: A case series and review of the literature.Int Orthop2012;36:1907-13.

3. SchneiderbauerMM, GullerudR, HarmsenWS, ScullySP. Fibular osteosarcomas: Contaminated margins may not impact survival.Clin OrthopRelat Res2007;456:182-7.

4. LaitinenM, HardesJ, AhrensH, GebertC, LeidingerB, LangerM, et al. Treatment of primary malignant bone tumours of the distal tibia.Int Orthop2005;29:255-9.

5. DieckmannR, AhrensH, StreitbürgerA, BudnyTB, HenrichsMP, ViethV, et al.Reconstruction after wide resection of the entire distal fibula in malignant bone tumours.Int Orthop2011;35:87-92.

6. MonsonDK, VojdaniS, DeanTJ, Louis-UgboJ. Lateral ankle stabilization after distal fibular resection using a novel approach: A surgical technique.Clin OrthopRelat Res2014;472:1262-70.

7. EnnekingWF, DunhamW, GebhardtMC, MalawarM, PritchardDJ. A system for the functional evaluation of reconstructive procedures after surgical treatment of tumors of the musculoskeletal system.Clin OrthopRelat Res1993;286:241-6.

8. MohlerDG, CunninghamDC.Adamantinoma arising in the distal fibula treated with distal fibulectomy: A case report and review of the literature.Foot Ankle Int1997;18:746-51.

9. Norman-TaylorFH, SweetnamDI, FixsenJA. Distalfibulectomy for Ewing's sarcoma.J Bone Joint Surg Br1994;76:559-62.

10. KanayaK, WadaT, KuraH, YamashitaT, UsuiM, IshiiS.Valgus deformity of the ankle following harvesting of a vascularized fibular graft in children.J ReconstrMicrosurg2002;18:91-6.

11. JonesRB, IshikawaSN, RichardsonEG, MurphyGA. Effect of distal fibular resection on ankle laxity.Foot Ankle Int2001;22:590-3.

12. MannRA, RongstadKM. Arthrodesis of the ankle: A critical analysis.Foot Ankle Int1998;19:3-9.

13. DurakK, BilgenO, KaleliT, AydinliU. Distal fibula resection in osteochondroma.J Int Med Res1996;24:381-6.

14. deGauzy JS, KanyJ, CahuzacJP. Distal fibular reconstruction with pedicled vascularized fibular head graft: A case report.J PediatrOrthop B2002;11:176-80.

15. EgerW, SchörleC, ZeilerG. Giant cell tumor of the distal fibula: Fifteen-year result after en bloc resection and fibula reconstruction.Arch Orthop Trauma Surg2004;124:56-9.

16. PickeringR. Arthrodesis of ankle, knee, and hip. In: PickeringRM, editors. Campbell's Operative Orthopaedics. 10th ed. St Louis, MO, USA: Mosby; 2003.

17. SaridisAG, MegasPD, GeorgiouCS, DiamantakisGM, TyllianakisME. Dual-fibular reconstruction of a massive tibial defect after Ewing's sarcoma resection in a pediatric patient with a vascular variation.J PediatrOrthop2011;31:297-302.

18. VaseenonT, SaengsinJ, KamintaA, PattamapaspongN, SettakornJ, PruksakornD.Ankle ligament reconstruction after wide resection of the osteosarcoma of the distal fibula: A case report.BMC Res Notes2017;10:769.

Conflict of Interest: NIL
Source of Support: NIL

How to Cite this Article

Pruthi M, Virk J D, Garg L, Goyal S, Sharma A | An Interesting Reconstruction Option after Resection for a Distal Fibular Osteosarcoma: A Case Report | Journal of Bone and Soft Tissue Tumors | January-April 2020; 6(1): 13-16.