Original Article
Journal of Bone and Soft Tissue Tumors 2018 July-Dec;4(2):11-13

Osteosarcoma of Extragnathic Skull Bones-clinicopathological Profile of Eight Cases

Mahfooz Basha Mohamed[1], Jayasree Kattoor[2],Kusumakumary Parukuttyamma[3], Geetha Narayanan[4], Anitha Mathews[2], Thara Somanathan[2]

Abstract

Osteosarcoma is the most common primary malignant tumor of bone, usually arising from the metaphysis of the long bones around the knee joint. In 6-13% cases they are located in the head and neck region, of which maxilla and mandible are the most common sites. Osteosarcoma involving the extra-gnathic craniofacial bones account for less than 2% cases. We report eight such cases of osteosarcoma involving this unusual location in the last three years (2011 -2014) and present their clinicopathological profile. Seven patients were under 15 years of age and one patient was 37 years old. Out of the eight cases, four were males and four were females. The location of the tumor included occipital bone, parietal bone, external auditory canal, nasal bone and mastoid. Two patients presented as multicenteric disease with multiple lesions in the skull and elsewhere. Two patients succumbed to the disease while five patients are on follow up. One patient was lost to follow up.A complete en-bloc dissection of the tumor with free margins is a challenge for the operating surgeons. Radiologically they can simulate non-neoplastic lesions or benign tumors as well.These tumors pose a unique therapeutic challenge owing to their unusual location and require a multidisciplinary team approach for management of the patient.

Keywords: Extragnathic, skull, bone, osteosarcoma.

Introduction

Osteosarcoma is a primary malignant neoplasm bone with a slight male preponderance and it has a predilection forlong bones of the extremities. It typically arises from the metaphysis of the long bones. The distal femur and proximal tibia are the most common sites of involvement [1]. Involvement of the skull accounts for 6-13% of the total cases [2]. In the skull, mandible is the most common site of involvement. The extragnathic sites are even rarer and comprise less than 2 % of osteosarcomas [3]. Histologically the conventional types of osteosarcomas are high grade tumorsand are the most commonly encountered osteosarcomas in practice.They are further classified into many subtypes depending on the cellular morphology and matrix formation, of which the osteoblastic, fibroblastic and chondroblastic subtypes are the most common.The other histological types of osteosarcomas aretelangiectatic, low grade central, small cell,parosteal, periosteal and high grade surface osteosarcomas [4]. The subtypes of conventional osteosarcomas are not associated with choice of therapeutic intervention and do not have prognostic significance [5]. Osteosarcomas are usually limited to a single site and said to be multicenteric when more than one site is involvedand there is no evidence of pulmonary metastasis. Multicenteric osteosarcomas account for about 1.5% of the total cases of osteosarcomas[6].While most osteosarcomas are idiopathic and termed as being primary, there are some well knownpredisposing conditionsthat are associated with an increase in the risk of developing osteosarcoma like Paget's disease, fibrous dysplasia, previous radiation etc. These types of osteosarcomas are referred to as the secondary type [7]. The extragnathic location of osteosarcoma is associated with a negative prognostic impact as compared to the other sites.This can be attributed to the complex anatomy of the skull which makes it a challenge to achieve disease free margins after surgical resection. Radiotherapy and chemotherapy are also used in the treatment of extragnathic osteosarcomas [8]. Thus extragnathic osteosarcomas require a highly skilled multidisciplinary team for effective management of the patient.

[1]Department of Laboratory Medicine, GKNM Hospital, Coimbatore 641006, Tamil Nadu, India.
[2]Department of Pathology, Regional Cancer Centre, Trivandrum 695011, Kerala, India.
[3]Department of Paediatric Oncology, Regional Cancer Centre, Trivandrum 695011, Kerala, India.
[4]Department of Medical Oncology, Regional Cancer Centre, Trivandrum 695011, Kerala.

Address of Correspondence
Dr. JayasreeKattoor,
Department of Pathology, Regional Cancer Centre, Trivandrum-695011, Kerala, India.
Email:jayasreeramdas@gmail.com

Material and Methods

We reviewed all cases of osteosarcomas reported in the period July 1st 2011 to June 30th 2014.During that period we had 198 cases of osteosarcoma. The site of involvement was checked in the patient records which also included the radiology images and reports. We then shortlisted all cases that involved the skull bones, excluding the cases with mandibular involvement. There were 8 cases of extragnathic osteosarcomas and these included 2 cases that presented with multicenteric disease.The clinicopathological profile of these patients was then analyzed.

Results

Extragnathic osteosarcomas at our centre

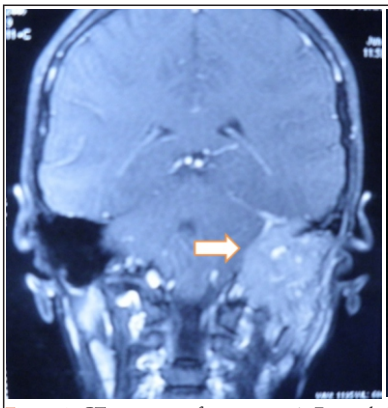

Figure 1: CT scan image from case no.1 -Expansile lytic lesion in left mastoid with cerebellar compression.

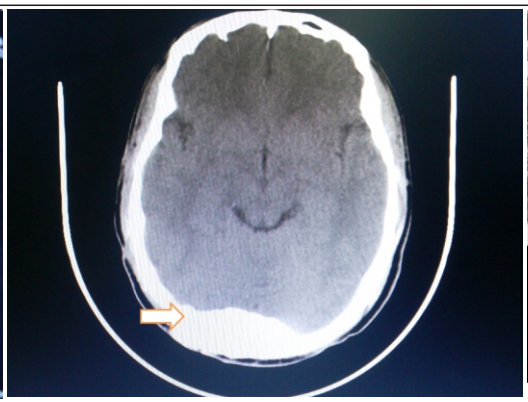

Figure 2: CT scan image from case no.4 -Sclerotic lesion in the occipital bone with cortical breaks.

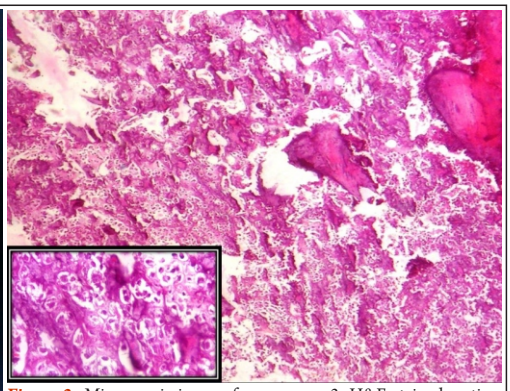

Figure 3: Microscopic images from case no.3, H&E stained section showing high grade osteoblastic osteosarcoma. Inset shows pleomorphic cells with osteoid matrix.

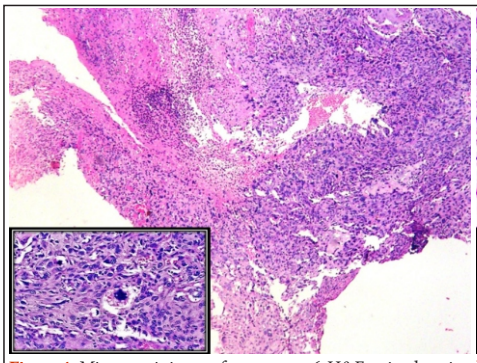

Figure 4: Microscopic images from case no.6, H&E stained section showing high grade osteoblastic osteosarcoma. Inset shows highly pleomorphic cells with lacy osteoid matrix.

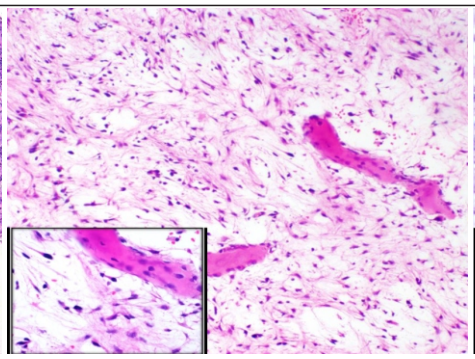

Figure 5: Microscopic images from case no.7-H&E stained section showinglow grade osteosarcoma. Inset shows cells with mild nuclear atypia.

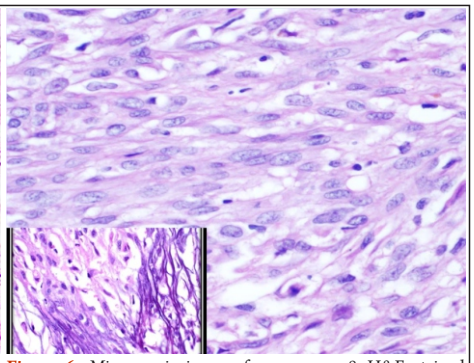

Figure 6: Microscopic images from case no.8--H&E stained section showing fibroblastic osteosarcoma. Inset shows spindle shaped cells with a fibrous matrix.

accounted for 4.04 % of the total cases of osteosarcomasduring the three years of study period.The eight cases studied showed an equal gender distribution and all cases were below 15 years of age except for one female patient with low grade osteosarcoma, who was 37 years old. The youngest case was 1.5 years old.One patient was a known case of bilateral retinoblastoma. Histologically, seven cases were high grade osteosarcomas (87.5%) while there was only one case of a low grade osteosarcoma (12.5%). Seven cases were of the osteoblastic subtype (87.5%) whereas one was a fibroblastic osteosarcoma (12.5%).Two patients had multicenteric disease of which one died and the other was lost to follow up. Of the eight cases, two patients (25%) succumbed to the disease while one was lost to follow up (12.5%). The rest of the five cases were on regular follow up (62.5%).

Discussion

In our study of eight cases (Table 1) we found that the extragnathic osteosarcomas at our centre account for about 4.04% of the total cases of osteosarcomain the study period. This proportion is higher as compared to what is reported in the literature(less than 2%) [9].Craniofacial osteosarcomas are most frequently seen in the third or fourth decade of life and in our series the majority of the cases(62.5%) were between 12-15 years of age [10].The average age of presentation was 13.8 yrs.Gnathic and extragnathic osteosarcomas show a male predilection [11]. Our study had eight cases and showed an equal distribution amongst both the genders. Secondary subtype of osteosarcomas is considered to be more common in the skull bones. Paget's disease, prior exposure to radiation, fibrousdysplasia, hereditary retinoblastoma etc., can be associated with an increased risk of osteosarcomas [12]. In our series only one patient had a history of being treated for bilateral retinoblastoma (Case no.6).She was on regular follow up for the disease and 13yrs after the diagnosis of retinoblastomapresented with nasal block and headache. On further evaluation,she was diagnosed to have a high grade osteoblastic osteosarcoma. She then underwent surgery, which was followed by chemotherapy. However she later died due to progressive disease a few years later. Multicenteric involvement was seen at presentationtwo patients (cases 2 and 3).The two cases had multiple skull lesions and also disease involving other bones.When the involvement is confined to the bones and does not involve the lungs, the disease is considered to be multifocal and not metastatic. A large dominant lesion when present would favor a metastatic disease where the neoplastic cells are thought to have spread via the lymphatic channels or by embolization through the marrow sinusoids [13]. The two cases with multicenteric osteosarcomas in our series

Table1.Clinicopathological profile of 8 cases of Extragnathic Osteosarcomas.

Detail	Case 1	Case 2	Case 3	Case4	Case5	Case 6	Case 7	Case8
Age	13	7	12	15	12	13	37	1.5
Gender	Male	Male	Male	Male	Female	Female	Female	Female
Site	Mastoid	Skull, jaw, radius,ulna,	Skull, Femur,tibia, vertebra,ribs	Occipital bone	Parietal bone	Nasal bone	Mastoid	Supra-sellar region
Primary /Secondary	Primary	Primary	Primary	Primary	Primary	Had Bilateral Retinoblastoma	Primary	Primary
OS Grade	High grade	High grade	High grade	High grade	High grade	High grade	Low grade	High grade
OS	Osteo-blastic	Osteo-blastic	Osteo-blastic	Osteo-blastic	Osteo-blastic	Osteo-blastic	-	Fibro-blastic
Type Follow up	Expired	Expired	Expired	Expired	Expired	Expired	On follow up	Lost to follow up

neither had pulmonary involvement nor any dominant lesion in any site. Thus they were considered to be multiple primaries and not a metastatic disease.Such cases are thought to be related to retinoblastoma gene or p53 mutationsetc. [14]. The presenting complaints of extragnathic osteosarcomas are symptoms like pain, proptosis, headache,and visual disturbancesetc. which are due to the compression of the tumor on the neighbouringstructures [15]. Radiological evaluation with a plain CT scan delineates the tumor clearly which can either present as a lytic or a sclerotic lesion giving rise to diagnostic dilemmas. Two such examples from our case series are illustrated in Fig1 and 2.One of them was a lytic lesion in the mastoid (case 1) with compression of the cerebellum and the other was a sclerotic lesion in the occipital bone (case 4). A contrast enhanced CT scan further helps to determine the presence of soft tissue involvement and also the extent of the disease [16]. Histologically seven out of eight cases were high grade (87.5%) and one case was a low grade osteosarcoma (case.7). All the high grade cases showed osteoblastic histology except for one (case.8) which was of the fibroblastic type (Fig.3-6). Following diagnosis, the mainstay of treatment is surgical resection with disease free margins.This is a challenging task even in expert hands as many important anatomical structures may be present in close proximity to the tumor. Radiation therapy with adjuvant or neoadjuvant chemotherapy is also used in the treatment of craniofacial osteosarcomas [17]. A team of multiple specialists including radiologists, pathologists, ENT surgeons, head and neck surgeons, radiation oncologists etc. is therefore required for the management of such cases. The overallprognosis of extragnathic osteosarcomas is less favorable as compared to the other sites, mostly due to the fact that a complete surgical resection is not always possible [8].Six patients in our series died within 5 years of diagnosis (85.7%)and one was lost to follow up.One of the patients is disease free, four years after surgery and is on follow up till date.

Conclusions

Extragnathic osteosarcomas are rare tumors and we report a series of eight such cases with their clinicopathological profile. They pose unique diagnostic and therapeutic challenges. Their treatment requires a multidisciplinary team effort with good expertise for their management.

References

1. G. Ottaviani and N. Jaffe, The epidemiology of osteosarcoma. Cancer Treatment and Research, 2009; Vol. 152, pp. 3–13.

2. Oda D, Bavisotto L M, Schmidt R A. et al., Head and neck osteosarcoma at the University of Washington. Head Neck. 1997; 19(6):513–523.

3. Santhosh Kumar N, Elizabeth Mathew Iype, Shaji Thomas, JayasreeK,SivaramanGanesan.Osteogenic sarcoma of mastoid bone. Journal of Case Reports 2014; 4(2):334-337.

4. Fletcher CD, Bridge J, Hogendoorn PC, Mertens F, Eds. The World Health Organization Classification of Tumours of Soft Tissue and Bone. Lyon, France: IARC; 2013.

5. Jo, Vickie Y. et al. Refinements in Sarcoma Classification in the Current 2013 World Health Organization Classification of Tumours of Soft Tissue and Bone Surgical Oncology Clinics , Volume 25 , Issue 4 , 621 – 643.

6. Corradi D. et al.,Multicentric Osteosarcoma: Clinicopathologic and Radiographic Study of 56 Cases, American Journal of Clinical Pathology, Volume 136, Issue 5, 1 November 2011, Pages 799–807.

7. Hoch M, Ali S, Agrawal S, Wang C, Khurana JS. Extra skeletal Osteosarcoma: A case report and review of the literature. Radiology Case. 2013; 7(7):15-23.

8. Jasnau S, Meyer U, Potratz J, et al. Craniofacial osteosarcoma: experience of the cooperative German-Austrian-Swiss osteosarcoma study group. Oral Oncol 2008; 44(March (3)):286–94.

9. VijayaKamble, KajalMitra, ChetanaRatnaparkhi, AkshayKapila. Primary Osteogenic Sarcoma of Zygomatic Arch: A Case Report, with World Literature Review. Journal of Evolution of Medical and Dental Sciences 2014; Vol. 3, Issue 36, August 18; Page: 9494-9499, DOI: 10.14260/jemds/2014/3226.

10. Hadley C, Gressot LV, Patel AJ, Wang LL, Flores RJ, Whitehead WE, et al. Osteosarcoma of the cranial vault and skull base in pediatric patients. J NeurosurgPediatr 2014; 13: 380-5.

11. Brad W. Neville, Douglas D. Damm, Angela C. Chi, Carl M. Allen.Oral and Maxillofacial Pathology 4th Edition,Elsevier Health Sciences;2015.Chapter 14:p.614.

12. Horvai A, Unni KK. Premalignant conditions of bone. Journal of Orthopaedic Science. 2006; 11(4):412-423.

13. Gon S, Kundu T, Ghosh BN. Synchronous multifocal osteosarcoma with small cell histological variant: A double rarity. Clin Cancer Investig J 2016; 5:533-6.

14. Currall VA, Dixon JH. Synchronous multifocal osteosarcoma: Case report and literature review. Sarcoma 2006; 2006:53901.

15. Mathkour M, Garces J, Beard B, et al. Primary high-grade osteosarcoma of the clivus: a case report and literature review. World Neurosurg 2016; 89:730.e9–13.

16. Meel R, Thulkar S, Sharma MC, Jagadesan P, Mohanti BK, Sharma SC, et al: Childhood osteosarcoma of greater wing of sphenoid: case report and review of literature. J PediatrHematolOncol 34:e59–e62, 2012.

17. Thiele OC, Freier K, Bacon C, et al. Interdisciplinary combined treatment of craniofacial osteosarcoma with neoadjuvant and adjuvant chemotherapy and excision of the tumour: a retrospective study. Br J Oral MaxillofacSurg 2008;46:533-6.

Conflict of Interest: NIL
Source of Support: NIL

How to Cite this Article

Mohamed MB, Kattoor J, Parukuttyamma K, Narayanan G, Mathews A, Somanathan T. Osteosarcoma of Extragnathic Skull Bones-clinicopathological Profile of Eight Cases. Journal of Bone and Soft Tissue Tumors July-Dec 2018;4(2): 11-13.